

423. Hypaque contrast material is _____ and when injected into the heart causes an immediate _____ in cardiac output.

- a. Hypertonic, Increase
- b. Hypertonic, Decrease
- c. Hypotonic, Increase
- d. Hypotonic, Decrease

ANSWER b. Hypertonic, Decrease. It is hypertonic and high in osmolarity. It is somewhat toxic to the heart and other tissues resulting in a sudden drop in BP and CO. You see this on every coronary angiogram.

The hypertonicity of the older contrasts is six times that of blood. When injected it's high tonicity and osmolarity pull tissue fluids into the vascular space. Within several minutes this leads to increase in preload that can push some patients into CHF. As the vascular volume increases the increased preload usually leads to a mildly increased cardiac output post cath. Osmolarity and osmolality are the same. Both deal with osmotic pressure.

See: Grossman, chapter on "Principles of angiography."

Keywords: hypertonic contrast causes increased preload risking CHF

424. What chemical element in contrast material makes it radiopaque to X-rays?

- a. Calcium
- b. Iodine
- c. Barium
- d. Lead

ANSWER b. Iodine. All vascular contrast media are organic compounds including the chemical element Iodine on the benzene ring. It is a heavy metal which absorbs X-rays. This imparts it's essential "radiopaque" quality.

See: Grossman, chapter on "Angiography: Principles..."

Keywords: Iodine in contrast = radiopaque

425. Older angiographic contrast agents such as Hypaque or Renografin commonly overload the blood volume of a patient in CHF. New contrast agents such as Ioxaglate (Hexabrix) and Iohexol (Omnipaque) do not increase the preload as much because of their:

- a. Low osmolarity
- b. Low Na⁺ and K⁺ content
- c. Higher radio-opacity per cc
- d. Increased ionization in solution

ANSWER a. Low osmolarity. The reason that these Low Osmolar Contrast Media (LOCM) do not overload the blood volume is due to their low osmolarity (osmolality). Any high volume contrast injection suddenly increases the circulating blood volume. Besides the 30-40 cc of contrast added to the system, the high osmolarity of the contrast suddenly pulls plasma into the vascular space through osmotic action. It is analogous to eating a salty pork dinner. As a result, you retain water. Low Osmolar contrast Media helps maintain normal fluid balance.

The sudden increase in blood volume following LVgram dramatically increases preload and LV EDP. This may exacerbate a CHF patient's pulmonary edema.

See: Grossman, chapter on "Cardiac Ventriculography."

Keywords: Less volume overload with low osmolar contrast

430. A patient's LV angiogram shows apical hypokinesis during sinus rhythm. But following one PVC the compensatory beat shows significantly improved EF. This post-"PVC potentiation" of LV contractility probably indicates:

- a. Reversible apical ischemia
- b. Irreversible apical infarcted area
- c. Recent LAD occlusion
- d. Old LAD occlusion

ANSWER a. Reversible apical ischemia. Grossman says "Segmental dysfunction of the Left Ventricle can be caused by ischemia or infarction. Segments whose abnormal wall motion is caused by ischemia show improvement in systolic motion, whereas segments whose abnormal wall motion is due to infarction fail to improve. A single ventricular premature beat is introduced during left ventriculography and is followed by a compensatory pause - then a potentiated beat. Segmental wall motion during one of the preceding sinus beats is compared to that of the post-extra-systolic beat. Left ventricles with asynergic wall motion during a preceding sinus beat which improves on the potentiated beat are ischemic, whereas those in which asynergy is similar on the preceding sinus beat and on the post-extra-systolic beat are infarcted."

This PVC may be introduced with a pacemaker or by irritating the ventricle while pulling back a RV catheter. Viable ischemic myocardium may also be evaluated on LV-gram post Epinephrine, Dobutamine, or nitroglycerine administration. As with post-extra-systolic potentiation, improved contractility indicates reversible ischemia.

See: Grossman, chapter on "Cardiac Ventriculography." **Keywords:** post-PVC potentiation = reversible ischemia

437. The cutoff between normal and abnormal LV function is considered to be an EF of:

- a. 10%
- b. 30%
- c. 50%
- d. 70%

ANSWER c. 50%. EF is the most commonly used indicator of LV function and a good predictor of patient survival.

50% is usually the cutoff for normal. Kennedy found that 94% of normal individuals have an EF between 51% and 83%.

See: Grossman, chapter on "Cardiac Ventriculography."

Keywords: normal EF > 50%

440. Following LV-angiography, this LV-AO pullback pressure was recorded on X200. What abnormality is indicated?

- a. None, this is normal pressure amplification in periphery
- b. Aortic stenosis
- c. Coarctation of Aorta
- d. Idiopathic Hypertrophic Subvalvular Stenosis

ANSWER a. No abnormalities are seen except the AO systolic is slightly higher than systolic LV, seemingly a hemodynamic impossibility. (AO pressure can't be higher or blood would flow backwards during systole). However, the further down the AO the catheter tip is withdrawn, Systolic pressure increases due to wave reflections.

THIS IS NORMAL PRESSURE AMPLIFICATION IN PERIPHERY. Slightly higher systolic pressure is commonly seen when the catheter is pulled back into the descending AO.

See: Grossman, chapter on "Pressure measurements"

Keywords: LV-AO pullbacks

466. Aneurysmal LV walls which bulge in systole are termed:

- a. Akinetic
- b. Asyneresis
- c. Dyskinetic
- d. Hypokinetic

ANSWER c. Dyskinetic. A weakened LV wall can bulge in systole just like an aortic aneurysm. They are termed dyskinetic ("dys-" prefix means disordered or bad). It is also termed "paradoxical motion" because it moves the wrong way. Dyskinetic LV walls steal stroke volume from the heart and absorb the LV contraction. They are common immediately following myocardial infarction. They usually heal into a stiff akinetic scar which does not steal as much stroke volume. Open heart surgery can be done to excise the dead bulging aneurysm or scar to improve LV function.

See: Medical Dictionary **Keywords:** Dyskinetic LV

292. You are assisting a new cardiologist do a right heart cath on a cyanotic child. Before inflating the balloon he asks you "What should I use to inflate this balloon?" You should answer_____.

- a. "Air"
- b. "CO2"
- c. "Sterile Saline"
- d. "50%-50%, contrast and saline"

ANSWER b. CO2 is 20 times more soluble in blood than air. If the balloon breaks or leaks in the right heart it will be more quickly absorbed. Since cyanotic shunts move across the septum in a R-L direction, some of the gas may pass through the R-L shunt. If it does embolize into the left heart it might lead to a dangerous arterial embolism or stroke.

Get the CO2 from a CO2 tank off the table.

O2 gas is heavier than air, so let it bleed into a glass or basin through a sterile tube on the table. Then fill the balloon syringe by aspirating CO2 from the bottom of the glass. Use this to inflate the balloon. One problem with CO2 is that it diffuses rapidly through rubber. So you may have to replenish the CO2 frequently.

Never inflate a Swan-Ganz balloon with any fluid, especially contrast! Its high viscosity may prevent you from removing it through the tiny catheter lumen.

See: Baim and Grossman, chapter on "Balloon-tipped Flow-directed catheters"

Keywords: Cyanotic kid □ use CO2 in Swan

294. -Which statement regarding the set-up of hemodynamic monitoring equipment is most correct?

- a. The system should only be flushed with saline to remove air bubbles at the time of set-up, prior to connection to the patient.
- b. The pressure cuff on the IV solution bag must be maintained at 200 mmHg
- c. All stopcock side-arm ports must be replaced with closed (dead-ender) caps
- d. A properly inflated pressure cuff on the IV solution bag along with an in-line continuous flush device provides a continuous flow rate of 10-20 ml/minute.

ANSWER c. All stopcock side-arm ports must be replaced with closed (dead-ender) caps. This prevents accidental opening to air which could allow contamination or blood leakage. Systems should be flushed whenever air bubbles or blood are present. Air bubbles should be vented up and out of the transducer. Blood should be flushed through the catheter back to the patient. pressure cuff on the IV solution bag must be maintained at 300 mmHg not 200. Normal continuous flow rates are 3-5 ml/hr not 10-20 ml/minute.

See: Darovic, chapter on "Pulmonary Artery Pressure Monitoring" and

<http://www.pacep.org/pages/start/ref.html?xin=asahq>

296. When inserting a Swan-Ganz catheter the balloon should be inflated in the:

- a. Sheath
- b. Femoral vein
- c. IVC-RA
- d. RV
- e. PA

ANSWER c. RA. The balloon should not be inflated until it reaches the large vena-cava or RA. If inflated in the sheath or small vein it may rupture the balloon or damage the vessel. In an average sized adult the RA is usually reached after inserting the catheter 15-20 cm from the Internal Jugular (I.J.) vein or 30 cm. from the femoral vein. The inflated balloon then floats downstream with the RA-RV-PA blood flow. **See:** Baim and Grossman, chapter on "Balloon-tipped Flow-directed catheters" **Keywords:** Inflate Swan balloon in RA

300. The most stable place to leave a Rt. Ht. catheter positioned is with the tip in the:

- a. RA
- b. RV
- c. PA
- d. PAW

ANSWER c. PA. Most monitoring catheters are left in the PA position because it produces fewer arrhythmias than the RA (PACs) or RV (PVCs). After obtaining a PA wedge the balloon is deflated to prevent obstruction of blood flow, and the catheter is pulled back out of wedge so it cannot damage the lung. Monitoring Swan-Ganz catheters may be left in the PA position long term.

See: Baim and Grossman, chapter on "Balloon-tipped Flow-directed catheters"

Keywords: PA most stable position

305. On the second day of pulmonary artery catheter monitoring an RV waveform is observed from the distal catheter port. Which one of the following is the most appropriate action?

- a. Advance the catheter 10 cm with the balloon deflated
- b. Switch monitoring lines to the proximal port of the catheter
- c. Inflate the balloon with 1.5 ml air and withdraw the catheter
- d. Inflate the balloon with 1.5 ml air and advance the catheter
- e. Leave in RV, you can still get PA systolic pressure from RV

ANSWER d. Inflate the balloon with 1.5 ml air to make a soft tip. Then advance the catheter until PA wedge waveform appears, and deflate the balloon. Check the waveform to assure it is in the PA. You do not want to insert the catheter deflated, because the hard catheter tip may lodge in and damage the RV or PA wall (remember the trabeculations in the RV). Neither, do you want to leave the tip in the RV because it causes PVCs and ventricular arrhythmias.

See: <http://www.pacep.org/pages/start/ref.html?xin=asahq>

306. All of the following statements regarding PA catheter insertion are true EXCEPT:

- a. Following vessel puncture, SaO₂ analysis of a withdrawn blood sample should be <95%.**
- b. Use a Pacerport Swan in patients with LBBB.**
- c. The major risk of internal jugular cannulation is carotid artery puncture.**
- d. Air embolism is of concern at the time of guidewire and catheter insertion.**

ANSWER a. Following vessel puncture, SaO₂ analysis of a withdrawn blood sample should be <95% is not true. The SvO₂ (not SaO₂) must be less than 85% to be sure you are in the vein. Patients may develop RBBB if the RBB is irritated during catheter passage through the RV. If the patient has pre-existing LBBB, complete heart block may ensue, requiring pacing via a pacerport catheter, a pacing Swan or external transcutaneous pacing. The carotid artery is close to the internal jugular. Take precautions against air embolism by placing the patient in the Trendelenburg position.

See: Darovic, chapter on "Pulmonary Artery Pressure Monitoring" and <http://www.pacep.org/pages/start/ref.html?xin=asahq>

308. To help prevent pulmonary artery rupture when wedging a Swan-Ganz catheter:

- a. Check the pulmonary artery occlusion pressure frequently**
- b. Withdraw PAC slightly if a PAOP waveform is obtained with inflation of <1.25 ml air**
- c. Advance PAC slightly if a PAOP waveform is obtained with inflation of <1.25 ml air**
- d. Always use 1.5 ml air to inflate the balloon for a PAOP**

ANSWER b. Withdraw PAC slightly if a PAOP waveform is obtained with inflation of <1.25 ml air. You want the catheter to wedge with <1.5 ml of air. But, if the wedge air volume is <1.25 the hard catheter tip may be exposed. Darovic says: "The following guidelines should prevent damage or rupture of the pulmonary artery:

1. Do not advance the catheter with the balloon deflated
2. Slow balloon inflation while continuously observing the PA waveform. Inflation is stopped immediately when the PA trace changes to a wedged pressure trace.
3. Do not inflate the balloon with fluid...
4. Keep the wedging time and the number of balloon inflation/deflation cycles to a minimum. If a close pulmonary artery diastolic/wedge pressure relationship exists, pulmonary artery diastolic pressure may be used to assess left atrial pressure.
5. Position the catheter tip in a central pulmonary vessel so that the full or nearly full recommended inflation volume produces the wedge waveform.
6. Avoid excessive catheter manipulation
7. Avoid irrigating the pulmonary artery lumen under high pressure. ... The damped tracing may be due to spontaneous wedging, and forced irrigation may produce rupture of the pulmonary artery."

See: Darovic, chapter on "Pulmonary Artery Pressure Monitoring" and <http://www.pacep.org/pages/start/ref.html?xin=asahq>

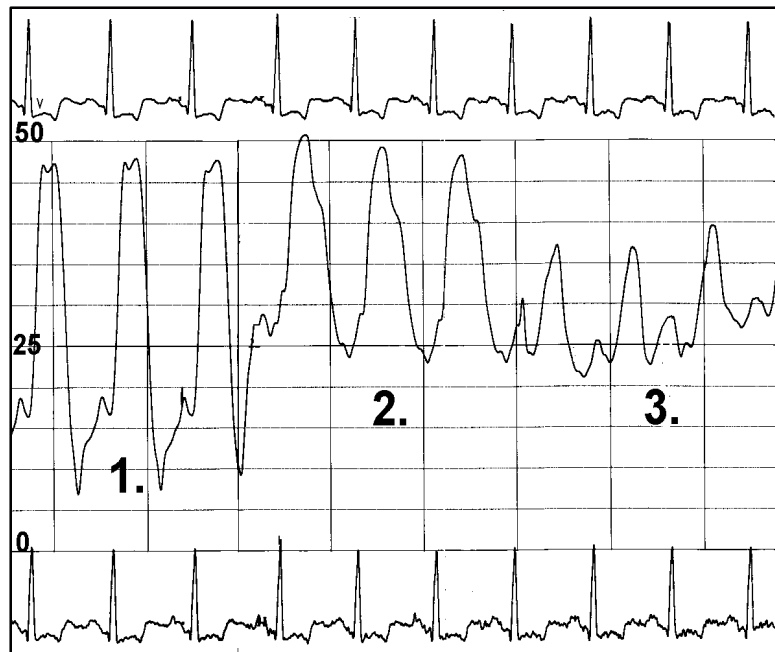
310. Which statement regarding thrombus formation on Swan-Ganz catheters is most correct?

- a. All intravascular monitoring catheters are thrombogenic.
- b. Heparin should be added to the IV solutions of all patients with a PA catheter.
- c. Catheters occluded by thrombus should be flushed vigorously with saline to clear the catheter.
- d. Thrombus begins to form on catheters only after 3 to 5 days in the vessel

ANSWER a. All intravascular monitoring catheters are thrombogenic. Even heparin does not guarantee they will not clot. However, many physicians are not using heparin for right heart cath or PA monitoring. And, if a catheter does become clotted, do NOT flush the catheter into the circulation. That causes an embolus. Darovic says: "Any catheter in the vascular system can promote thrombus formation, particularly in patients who have prolonged circulatory failure. . . . Prevention of catheter thrombus formation requires consideration of anticoagulation I hypercoagulable patients if pulmonary artery pressure monitoring is prolonged or if catheter insertion is known to have been traumatic."

See: Darovic, chapter on "Pulmonary Artery Pressure Monitoring" and <http://www.pacep.org/pages/start/ref.html?xin=asahq>

THIS PRESSURE TRACING SHOULD BE USED FOR THE NEXT 2 QUESTIONS



315. This pressure sequence shows a Swan-Ganz catheter passing from:

- a. PAW, PA, to RV (pullback)
- b. PAW, RV, to RA (pullback)
- c. RV, PA, PAW (advance)
- d. LV, AO, LA (pullback)

316. This patient has abnormal pressures indicating:

- a. Tricuspid stenosis
- b. Pulmonic stenosis
- c. Mitral stenosis
- d. Pulmonary hypertension

BOTH ANSWERS ARE LISTED BELOW CONSECUTIVELY:

315. ANSWER c. RV, PA, PAW (advance). The Balloon catheter was floated through the RV (#1), across the Pulmonic valve into the PA (#2), and finally into PA Wedge position (#3). Note how the first pressures resemble a square wave, and the PA a triangle wave. The RV and PA systolic pressures match. PA diastolic and wedge pressures match. The final tracing shows a sine wave pattern with a small "a" and large "v" waves. **See:** Kern, chapter on "Hemodynamics." **Keywords:** RV, PA, PAW insertion, pressure waveforms

316. ANSWER d. Pulmonary hypertension. RV and PA systolic pressures are high at 45-50 mmHg. This is far higher than the normal systolic of 25 mmHg. Mean wedge pressure is 32 mmHg. This elevated wedge pressure indicates probable congestive left heart failure. But, the high wedge has backed up into the right heart, causing pulmonary hypertension. The elevated RV-EDP of 17 mmHg indicates that the left heart failure has backed up into the right heart, causing its failure as well. Although, not shown on this tracing this patient had severe aortic stenosis.

See: Kern, chapter on "Hemodynamics." **Keywords:** Pulmonary Hypertension

319. Prior to pulling back a Swan-Ganz catheter to record PA-RV pressures you should _____.

- a. Inflate the balloon
- b. Deflate the balloon
- c. Flush the distal lumen of the catheter
- d. Flush the proximal lumen of the catheter

ANSWER b. Deflate the balloon. If you pull back an inflated balloon catheter across a valve, you may damage that valve. The balloon should be "up" when inserting and "down" when withdrawing the catheter. It won't hurt to flush the distal lumen through which your pressures are coming. It will reduce damping. But it is not necessary at this time.

See: Baim and Grossman, chapter on "Balloon-tipped Flow-directed catheters"

Keywords: deflate balloon when withdrawing

327. Which one of the following statements about abnormal central venous O₂ saturation (SvO₂) is most correct?

- a. SvO₂ values <0.60 indicate threatened tissue oxygenation
- b. SvO₂ values >0.80 indicate adequate or increased tissue oxygenation
- c. SvO₂ values <0.60 indicate low oxygen consumption
- d. SvO₂ values >0.80 indicate increased oxygen consumption

ANSWER a. SvO₂ values <0.60 indicate threatened tissue oxygenation. This low venous saturation suggests low cardiac output (wide A-V difference) and poor tissue oxygenation. Darovic says: "SvO₂ monitoring is a sensitive indicator of the oxygen supply/demand balance. When the SvO₂ values fall to less than 50 percent, the patient should be rapidly assessed for conditions that increase oxygen demand. . . . Acute changes in the patient's oxygen supply/demand balance may be simply and safely assessed in the clinical setting by two technologies. First, continuous SvO₂ monitoring [via Swan-Ganz fiberoptic catheters] ... Second, pulse oximetry can be used with cardiac index and hemoglobin values to estimate the amount of oxygen delivered to the body cells."

See: Darovic chapter on "Continuous Monitoring of Mixed Venous Oxygen Saturation (SvO₂)" and <http://www.pacep.org/pages/start/ref.html?xin=asahq>

328. Central venous pressure (CVP) can directly assess which 2 of the following?

- 1. RV function
 - 2. LV function
 - 3. Fluid volume status
 - 4. Myocardial contractility
- a. 1 & 2
 - b. 2 & 3
 - c. 3 & 4
 - d. 1 & 3
 - e. 2 & 4

ANSWER d. 1 & 3: RV function and Fluid volume status. To measure CVP, a catheter may be placed in the SVC or a Swan-Ganz catheter may be monitored from the RA port. CVP or RA pressure directly measures right heart preload and RV function. The RV filling pressures will be elevated in right heart failure (assuming no tricuspid disease). Darovic say: "The central venous pressure measurement also can be used to assess and manage intravascular volume status because pressure in the great thoracic veins generally correlates with the volume of venous return. The amount of blood that returns to the heart is normally ejected by the heart. Therefore, in patients with hypovolemia, a decreased CVP measurement is associated with a decreased cardiac output, whereas patients with volume overload typically have increased CVP and cardiac output."

CVP can indirectly monitor LV function, but only in normal young people. The frequent disparity between right and left heart function in critically ill patients requires a Swan-Ganz catheter so that each side of the heart can be evaluated independently.

See: Darovic, Chapter on "Monitoring Central Venous Pressure"

329. Which of the following is most likely to be associated with hypovolemia?

- a. Increased central venous pressure
- b. Decreased RV end-diastolic pressure
- c. Increased PA occlusion pressure
- d. Decreased heart rate

ANSWER b. Decreased RV end-diastolic pressure. Darovic says: "Progressive intravascular volume losses produce greater decrements in right atrial pressure and CVP. Patients with acute, profound hemorrhage may have measurements as low as minus 8 to minus 10 mmHg." In acute decompensated hypovolemic shock vasoconstriction increases to maintain BP, skin is cool & pale, along with signs of tachycardia, lactic acidosis, and hypoxemia.

See: Darovic, Chapter on "Monitoring the Patient in Shock" and <http://www.pacep.org/pages/start/ref.html?xin=asahq>

330. Which one of the following statements about the pulmonary artery occlusion pressure (wedge) is most correct?

- a. The pulmonary artery occlusion pressure is measured through the most proximal catheter port
- b. Inflation of the balloon momentarily stops the flow of blood and creates a static column of blood between the tip of the catheter and the left atrium
- c. The PAOP waveform always contains 3 positive waves (a, c, v)
- d. During inflation of the balloon the pulmonary artery pressure changes to a right ventricular waveform

ANSWER b. Inflation of the balloon momentarily stops the flow of blood and creates a static column of blood between the tip of the catheter and the left atrium. This static column transmits the LA pressure back to the catheter tip. Since LA is the filling pressure of the LV, wedge tells us about the LV filling pressure and LV function. The PA occlusion pressure (wedge) is measured through the distal catheter port, as it is directed into the pulmonary capillary bed. The wedge waveform will show a and v waves, but commonly no c wave is visible, because it merges with the a wave.

See: Darovic, chapter on "Pulmonary Artery Pressure Monitoring" and <http://www.pacep.org/pages/start/ref.html?xin=asahq>

333. Which one of the following statements about hemodynamic waveforms is most correct?

- a. Hemodynamic pressures rise during inspiration in a patient breathing spontaneously
- b. Hemodynamic pressures fall during inspiration in a patient receiving positive-pressure mechanical ventilation
- c. Hemodynamic pressures should be read at end-expiration in a patient breathing spontaneously
- d. Hemodynamic pressures should be read at peak-inspiration in a patient receiving positive-pressure mechanical ventilation

ANSWER c. Hemodynamic pressures should be read at end-expiration in a patient breathing spontaneously and when the patient is receiving mechanical ventilation. So end-expiration is always correct. The problem with mechanical ventilation is, end-expiration pressures tends to be at the bottom of the tracing, where it is normally at the top. Normal inspiration makes the pressures go down, while mechanical inspiration makes the pressures go up.

See: Darovic, chapter on "Pulmonary Artery Pressure Monitoring" and <http://www.pacep.org/pages/start/ref.html?xin=asahq>

334. Indications for diagnostic myocardial biopsy include all the following EXCEPT:

- a. Cardiac transplant patient follow up
- b. LV hypertrophy associated with untreated chronic systemic hypertension
- c. Restrictive cardiomyopathy (Amyloidosis, hemochromatosis...)
- d. Viral myocarditis and/or Endocardial fibrosis

ANSWER b. LV hypertrophy associated with untreated chronic systemic hypertension. Hypertrophy due to pressure overload, and is a major cause of primary myocardial hypertrophy. Whereas, in the other myocardial conditions listed, distinct histologic changes occur in the muscle secondary to infection, tissue deposits, or rejection. Definitive diagnose of many of these conditions can only be made with microscopic tissue analysis. This tissue sample must be taken during an invasive biopsy procedure. Cardiac biopsies are small bites of tissue taken from the Ventricular myocardium with one of the bioptome catheters described below.

See: Kern, Chapter "Special Techniques."

Keywords: Indications for biopsy

338. From what part of the heart are intracardiac myocardial biopsy samples normally taken?

- a. RV septum
- b. RV outflow tract
- c. Inferior RV wall
- d. LV free wall

ANSWER a. The RV septum is the safest area from which to take a sample. Being part of the LV septum, it is the thickest part of the RV . Overzealous sampling may perforate the RV wall, leading to pericardial tamponade. 4-5 samples should be taken from the RV. It is not usually necessary to sample LV because most of the diseases diagnosed are diffuse and effect both chambers. In addition, Kern states that sampling from the RV outflow tract (near the pulmonic valve) and inferior wall should be avoided.

See: Baim and Grossman, Chapter on "Myocardial Biopsy." and Kern, Chapter "Special Techniques."

Keywords: Biopsy samples usually RV septum

339. How much heparin should a patient receive for Right heart myocardial biopsy? How much for Left heart biopsy?

	<u>RT. HEART BIOPSY</u>	<u>LEFT HEART BIOPSY</u>
a.	None, - - -	None
b.	None, - - -	5000 u
c.	5000 u, - - -	None
d.	5000 u, - - -	5000 u

ANSWER b. None for RV, 5000 u for LV. Heparinization encourages the bleeding from biopsy sites and pericardial tamponade into perforations. Grossman states "*We avoid right ventricular biopsy in any patient with a Prothrombin time greater than 17 sec, any patient who is heparinized or any patient with a clinical coagulopathy. On the other hand, left ventricular biopsies are generally performed with systemic anticoagulation (heparin 5000 u), which is not reversed with protamine at the end of the procedure to minimize the risk of thrombus formation at the biopsy site.*"

<u>RT. HEART BIOPSY</u>	<u>LEFT HEART BIOPSY</u>
None, - - -	5000 u

Bleeding from the right side is more serious than emboli (they will be filtered by the lung). Whereas, emboli from the left side are more serious (possibility of stroke).

See: Baim and Grossman, Chapter on "Myocardial Biopsy."

Keywords: No heparin for RV biopsy, 5000 u for LV biopsy

340. The main hazard of myocardial biopsy is:

- a. Air embolism through the large sheath
- b. Bundle branch or complete heart block
- c. Coronary artery perforation and fistula
- d. Infection at the biopsy site
- e. Cardiac perforation

ANSWER e. RV perforation is the most dreaded complication since it can lead to fatal pericardial tamponade. The RV is only a few mm thick and with force any stiff catheter can perforate. That is why only septal wall samples are taken and heparin is not given with RV biopsy. Simple pericardial centesis usually cures the tamponade problem.

The other complications listed are also possible. This is a very safe procedure with approximately half the mortality of a left heart cath and coronaries (0.10% vs .05%).

See: Baim and Grossman, Chapter on "Myocardial Biopsy."

Keywords: Main complication biopsy = perforation

341. A complication of myocardial biopsy is inadvertent puncture through the ventricular free wall. What lifesaving measure should be considered if hypotension develops following this procedure?

- a. Thoracentesis
- b. Pericardial centesis
- c. Coronary Artery Bypass surgery
- d. Aortic Valve Replacement surgery

ANSWER b. Pericardial centesis. If blood build-up in the pericardial sack, causing restriction of ventricular filling, pericardial centesis may be lifesaving.

See: Baim and Grossman chapter on "Percutaneous Approach."

Keywords: with biopsy wall puncture - treat pericardial tamponade with Pericardio-centesis

342. Myocardial biopsy samples for light microscopic analysis are placed in a solution of:

- a. 10% formalin
- b. 56% formalin
- c. 5.0% Glutaraldehyde
- d. 50% Glutaraldehyde

ANSWER a. 10% formalin (formaldehyde) preserves the sample. 2.5% Glutaraldehyde solutions are used for electron microscopic analysis.

See: Baim and Grossman chapter on "Myocardial Biopsy."

Keywords: preserve biopsy samples in 10% formalin

343. Histologic signs of cardiac transplant rejection found in myocardial biopsy samples include all the following EXCEPT:

- a. Interstitial edema and inflammation
- b. Erythrocyte hemolysis
- c. Lymphocyte infiltration
- d. Myocyte necrosis

ANSWER b. Erythrocyte hemolysis is rupture of red blood cells. It may occur in hypertonic solutions or mechanical valve turbulence (hemolytic anemia), but not with transplant rejection. Braunwald says, "*The most important feature of post-transplant biopsies is the detection of lymphocyte infiltration and the presence of myocyte necrosis.*" That involves white blood cells (lymphocytes) rushing in to remove dying (necrotic) cardiac muscle cells (myocytes). The early stages of rejection also involve inflammation and edema of the transplanted myocardial cells.

See: Baim and Grossman, Chapter on "Myocardial Biopsy." and Braunwald, Heart Disease..., Chapter on "Heart and Lung Transplantation."

Keywords: histologic signs of rejection NOT Erythrocyte hemolysis